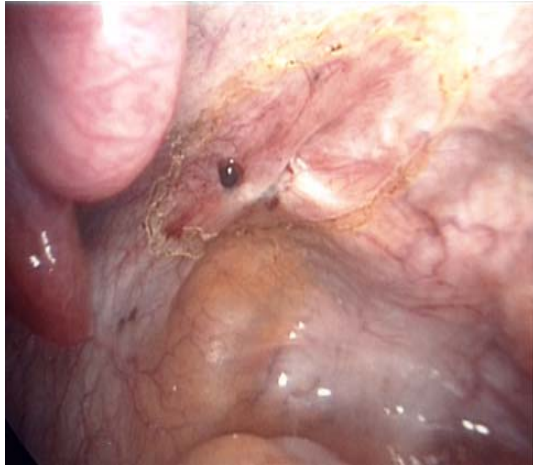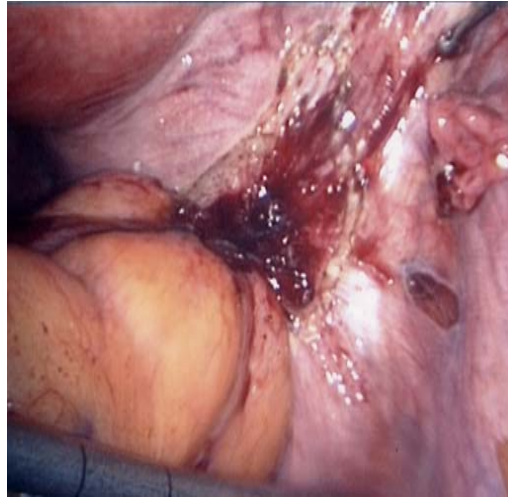


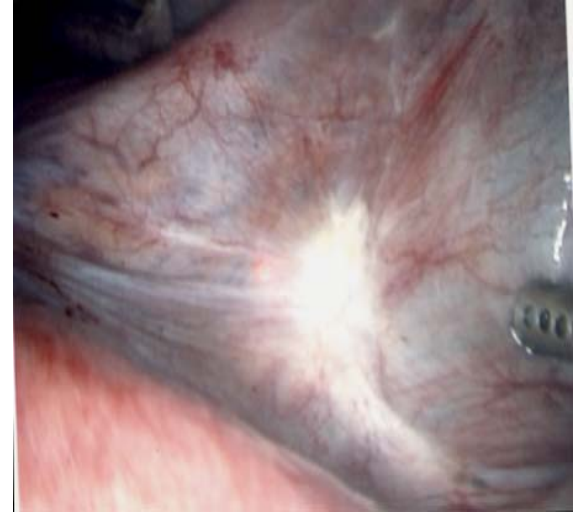Red, vascular lesion



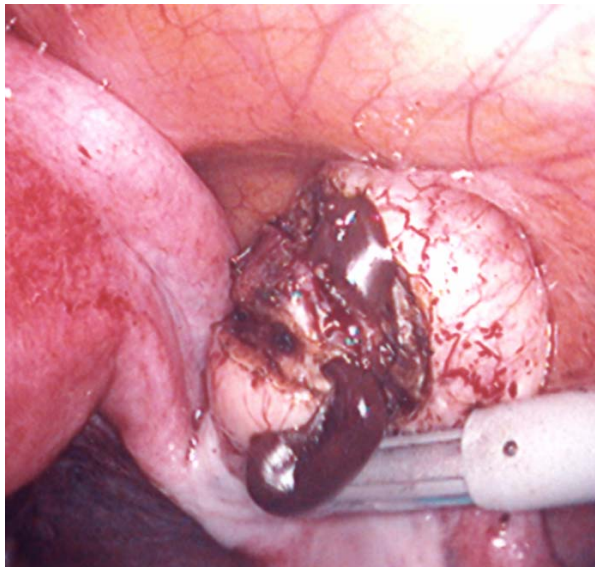
Invasive bowel implant



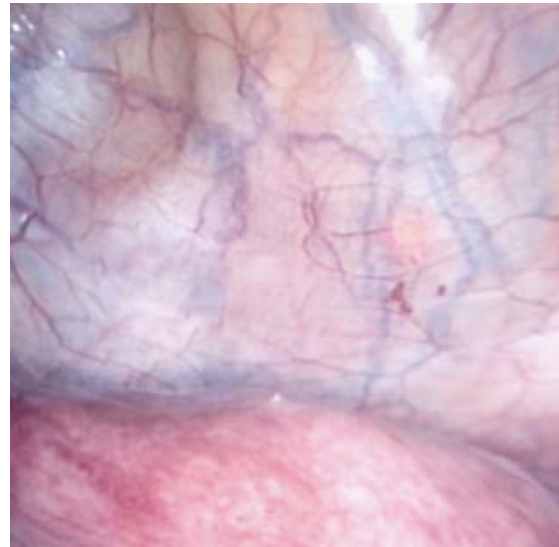
White fibrotic nodule



Endometrioma, R ovary



Bladder Endo



bowel Endo (bowel externa)

